

Artifacts and Pitfall Errors Associated With Ultrasound-Guided Regional Anesthesia. Part I: Understanding the Basic Principles of Ultrasound Physics and Machine Operations

Brian D. Sites, M.D., Richard Brull, M.D., F.R.C.P.C.,
Vincent W. S. Chan, M.D., F.R.C.P.C., Brian C. Spence, M.D.,
John Gallagher, M.D., Michael L. Beach, M.D., Ph.D., Vincent R. Sites, M.D.,
and Gregg S. Hartman, M.D.

Ultrasound guidance in regional anesthesia has grown in popularity over the past 5 years. Its attractiveness stems from the unprecedented ability to visualize the target nerve, approaching needle, and the real-time spread of local anesthetic.¹ As ultrasound experience grows within the regional anesthesia community, the limitations and challenges begin to declare themselves. Chief among these limitations are ultrasound-generated artifacts. Recognition of such optical events combined with an appreciation of the mechanisms involved supports a high quality ultrasound-guided regional anesthesia practice. The objective of this article (Part I) is to describe the physical properties of ultrasound most relevant to the regional anesthesiologist so that clinical sonographic imaging can be optimized and common ultrasound-generated artifacts (discussed in more detail in Part II²) can be recognized.

Ultrasound Generation, Frequency, and Wavelength

An ultrasound wave is a form of acoustic energy and is generated when multiple piezoelectric crystals inside a transducer (i.e., the probe) vibrate at high frequency in response to an alternating current. The rapid vibration, which is transmitted to the patient through a conductive gel, propagates longitudinally into the body as a short, brief series of compressions (high pressure) and rarefactions (low pressure). Each ultrasound wave is characterized by a specific wavelength (distance between pressure peaks) and frequency (number of pressure peaks per second). The propagation velocity of a sound wave (i.e., acoustic velocity) is fairly constant in the human body (c) and is approximately 1,540 meters per second. Therefore, in the human body, we can use the following equation:

$$(1) \quad c = \lambda \cdot f$$

where λ = wavelength, f = frequency, and c = 1,540 meters per second. In order to generate a clinically useful image, the ultrasound waves must bounce off of tissues and return to the probe. The probe, after emitting the wave, switches to a receive mode. When ultrasound waves return to the probe, the piezoelectric crystals will vibrate once again, this time transforming the sound energy into electrical energy. This process of transmission and reception can be repeated over 7,000 times a second and, when coupled to computer processing, will result in the generation of a real-time 2-dimensional image that appears seamless.

The degree to which the ultrasound waves reflect off of a structure and return to the probe will de-

From the Departments of Anesthesiology (B.D.S., B.C.S., J.G., M.L.B., G.S.H.) and Orthopedic Surgery (B.D.S.), Dartmouth Medical School, Dartmouth-Hitchcock Medical Center, Lebanon, NH; Department of Anesthesiology and Pain Medicine (R.B., V.W.S.C.), Toronto Western Hospital, University of Toronto, Toronto, Ontario, Canada; and the Department of Radiology (V.R.S.), Tufts University School of Medicine, Lahey Clinic, Burlington, MA.

Accepted for publication May 18, 2007.

Reprint requests: Brian D. Sites, M.D., Regional Anesthesia, Dartmouth-Hitchcock Medical Center, One Medical Center Drive, Lebanon, NH 03756. E-mail: brian.sites@hitchcock.org

© 2007 by the American Society of Regional Anesthesia and Pain Medicine.

1098-7339/07/3205-0010\$32.00/0

doi:10.1016/j.rapm.2007.05.005

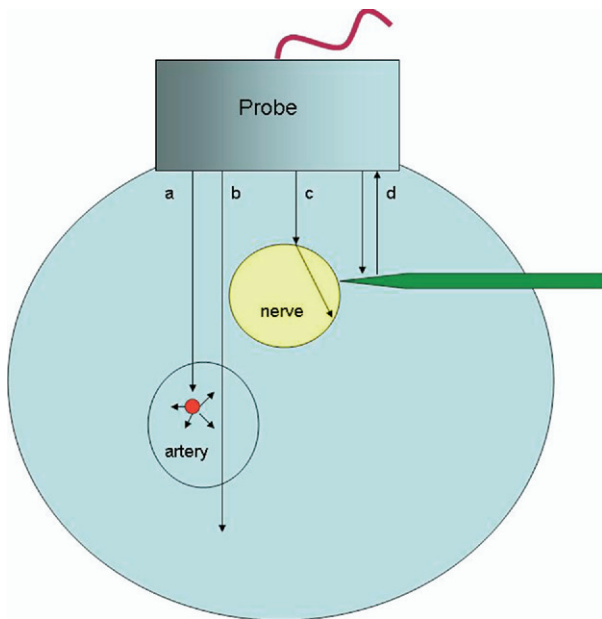


Fig 1. The many responses that an ultrasound wave produces when traveling through tissue. (a) Scatter reflection: the ultrasound wave is deflected in several random directions both to and away from the probe. Scattering occurs with small or irregular objects. (b) Transmission: the ultrasound wave continues through the tissue away from the probe. (c) Refraction: when an ultrasound wave contacts the interface between 2 media with different propagation velocities, the ultrasound wave is refracted (bent) depending upon the difference in velocities. (d) Specular reflection: reflection from a large, smooth object (such as the needle) which returns the ultrasound wave toward the probe when it is perpendicular to the ultrasound beam.

termine the signal intensity on an arbitrary gray scale.³ Structures that strongly reflect ultrasound generate large signal intensities and appear whiter or hyperechoic. In contrast, hypoechoic structures weakly reflect ultrasound and appear darker.

Ultrasound Interactions with Tissues

As the ultrasound waves travel through the body (Fig 1), they are influenced by reflection, refraction, and attenuation.⁴ When an ultrasound wave encounters a boundary between 2 different types of tissues, part of the acoustic energy is reflected and part is transmitted. A large and smooth reflector (e.g., the needle) acts like a mirror and is hence called a specular reflector. An irregular surface randomly scatters ultrasound and is referred to as a scattering reflector. Most neural images are generated based on scattering rather than specular reflection. The amount of ultrasound that is reflected is proportional to the difference in acoustic impedance (tendency to resist the passage of ultrasound) between adjacent tissues. The greater the mismatch

in acoustic impedance between 2 tissue interfaces, the more energy is reflected back towards the probe, resulting in 2 distinct images on the ultrasound screen. A bone/soft tissue interface, for example, reflects 43% of the incoming ultrasound waves. In contrast, a muscle/blood interface reflects 0.1% of the ultrasound waves.

Clinical pearls: The regional anesthesiologist is at a distinct advantage when the target nerve is surrounded by tissue that has a different acoustic impedance. For example, the sciatic nerve in the popliteal fossa is surrounded by adipose tissue. The large difference in acoustic impedance between the sciatic nerve and the adipose tissue causes the nerve to appear clearly hyperechoic relative to the hypoechoic surrounding adipose tissue (Figs 2 and 3). The reverse is true for the roots of the brachial plexus in the interscalene region. Here, there is a large difference in acoustic impedance between the fascial layers that envelop the plexus and the nerves themselves thereby causing the nerves to appear unmistakably hypoechoic relative to their surroundings (Fig 4).

When ultrasound passes through a tissue interface (nonreflected), it will likely change its direction of travel. This is a process known as refraction and occurs when the wave reaches a boundary that separates 2 tissues with different, however slight, acoustic velocities. Light also is refracted (Snell's law) and is the reason a fork appears bent when it is inserted into a glass of water. Refracted ultrasound may not contribute to successful imaging of the target structure if a significant amount of the ultrasound does not return to the probe. Refraction (as well as reflection away from the probe) occurs

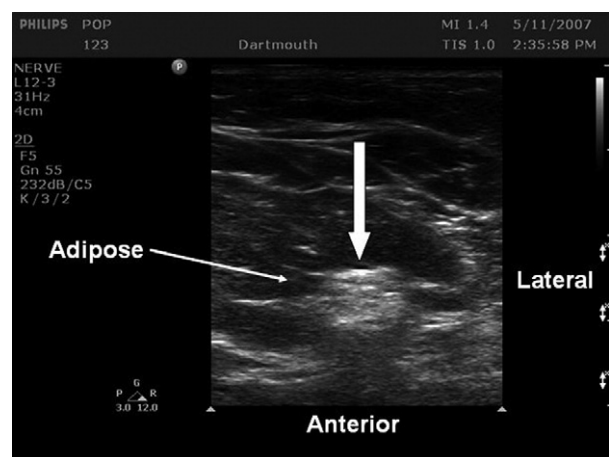


Fig 2. The short axis view of the sciatic nerve in the popliteal fossa. The large arrow indicates the nerve. The adipose tissue creates a distinct interface with the sciatic nerve which allows for an easy visual distinction between nerve and surrounding muscle. The nerve is hyperechoic (white) and the fat is hypoechoic (dark).

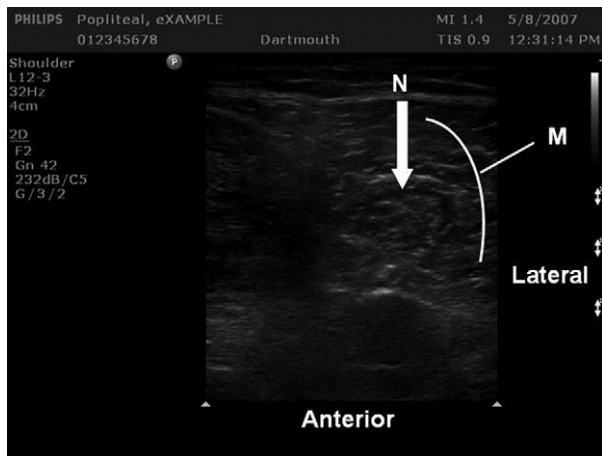


Fig 3. The short axis view of the sciatic nerve in the popliteal fossa. This image comes from an athlete. Note the difficulty in distinguishing the sciatic nerve from the surrounding muscle. N, sciatic nerve; M, muscle.

to a larger extent when the angle of incidence between the ultrasound beam and the structure is other than perpendicular.³

Clinical pearls: With respect to needle visualization, the goal of the anesthesiologist is to simultaneously minimize refraction and maximize reflection back toward the probe by keeping the needle perpendicular to the ultrasound beam as indicated in Figure 5A. With deeper nerve targets, the angle of incidence between the beam and needle becomes more parallel such that more ultrasound waves are redirected (by refraction and reflection) and fewer waves successfully return to the probe. The end result is that the needle becomes less visible (Fig 5B). For this reason, many providers prefer the out-of plane needle approach for deeper target nerves (Fig 6).

Attenuation is the progressive loss of acoustic energy as a wave passes through tissue.⁴ This results in a progressive decrease in the returning signal intensity as the ultrasound travels deeper into a tissue bed. The major source of ultrasound attenuation is the conversion of some of the acoustic (i.e., mechanical) energy into heat by a process known as absorption. Attenuation is directly related to the depth of beam penetration, the type of tissue being imaged, and varies indirectly with the frequency of the ultrasound waves. Different tissues will result in different degrees of attenuation. Attenuation is measured in decibels per centimeter of tissue (dB cm^{-1}) and is represented by the attenuation coefficient of the specific tissue. The higher the attenuation coefficient, the more attenuated the ultrasound waves are by the specified tissue. Examples of attenuation coefficients of different physiologic tissues are listed in Table 1. Figure 7 shows the impact

of frequency and depth on the attenuation of ultrasound.

Clinical pearls: While attenuation can have a profound negative impact on image quality, there are 2 important adjustments that can be made on the ultrasound machine that help to overcome some of the effects of attenuation. First, most machines allow the operator to artificially increase (or decrease) the signal intensity of the returning echoes from all points in the displayed field. This is accomplished by adjusting the gain control higher to increase the overall brightness. Second, most machines offer the operator the ability to control gain independently at specified depth intervals. This is known as time gain compensation. The time gain compensation should be progressively increased as the depth of penetration increases in order to compensate for the corresponding loss of signal intensity (Fig 8).

Resolution

Resolution refers to the ultrasound machine's ability to distinguish one object from another.⁵ The most important types of resolution for the regional anesthesiologist are axial, lateral, and temporal resolution.

Axial resolution refers to the machine's ability to separate 2 structures lying at different depths, parallel to the direction of the ultrasound beam. Axial resolution is roughly equal to one half of the pulse length. If the distance between 2 objects is greater than one half of the length of the ultrasound pulse, then the structures will appear as 2 separate objects (Fig 9). It follows then that higher frequency probes (shorter pulse lengths) produce the best axial reso-

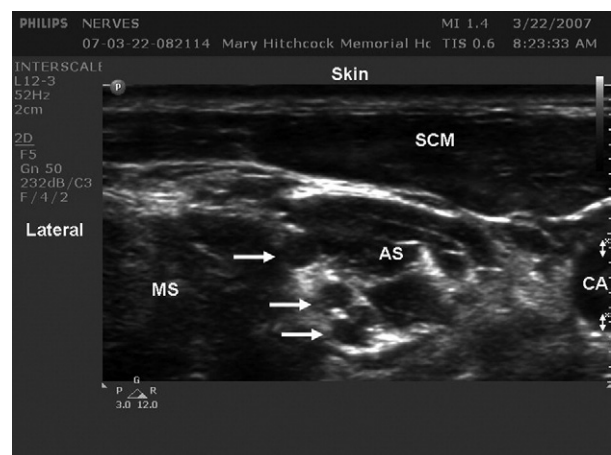


Fig 4. The short axis view of the interscalene brachial plexus. The arrows indicate the individual roots of the brachial plexus. Note the distinct hypoechoic nature of the roots in contrast to the hyperechoic fascial sheath. AS, anterior scalene muscle; CA, carotid artery; MS, middle scalene muscle; SCM, sternocleidomastoid muscle.

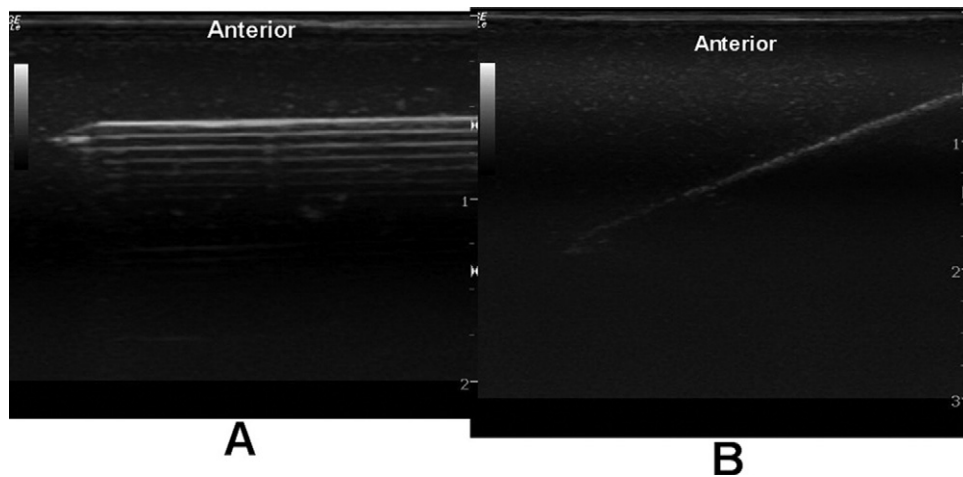


Fig 5. (A) Long axis image of an 18-gauge needle inserted in-plane with the ultrasound beam. Because the needle is inserted perpendicular to the ultrasound beam, it acts as a strong specular reflector, resulting in a large amount of ultrasound returning to the probe. (B) The angle of needle insertion was changed from perpendicular to more parallel, thereby increasing refraction and reflection away from the probe. This is the reason the image of the needle is degraded. Note also the reverberation artifact in (A), in which there are multiple needles visualized under the actual needle. Full discussion of this artifact can be found in Part II.²

lution. However, as described above, higher frequency ultrasound waves are more readily attenuated than lower frequency sound waves, resulting in poor tissue penetration.

Clinical pearls: High frequency transducer probes (e.g., 8-12 MHz) afford high axial resolution of superficial structures (e.g., axillary region) but have low tissue penetration. Low frequency probes (e.g., 4-7 MHz) allow for

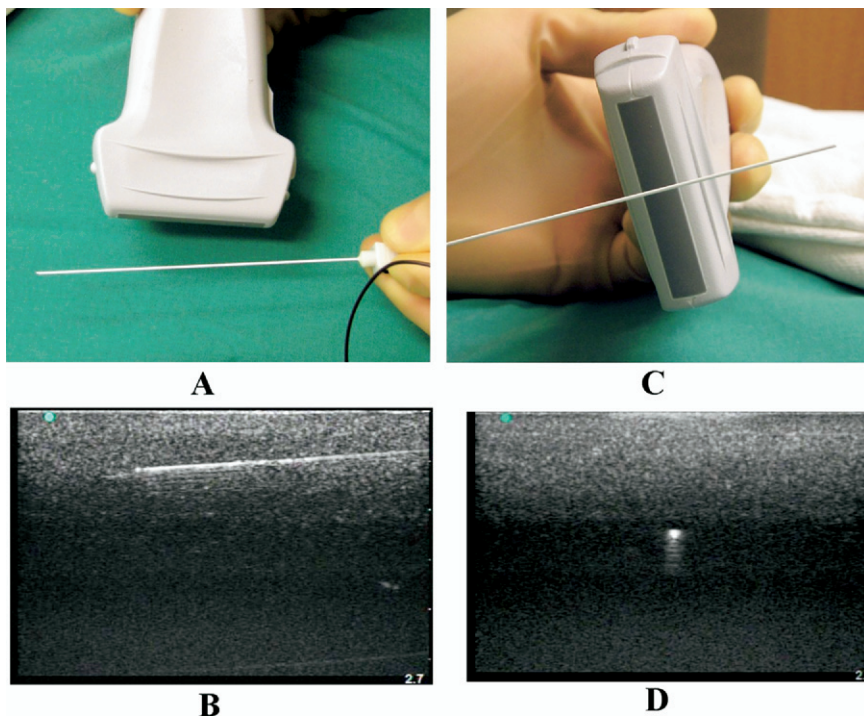


Fig 6. (A) The in-plane approach for needle insertion. (B) The corresponding needle image for the in-plane approach. (C) The out-of-plane approach for needle insertion. (D) The corresponding needle image for the out-of-plane approach. The out-of-plane approach has the disadvantage of only visualizing a portion of the needle on short axis. However, for deep blocks such as the transgluteal sciatic block, the out-of-plane approach may be preferred secondary to optimization of reflection toward the probe and minimization of refraction. This is secondary to the near perpendicular relationship of the needle to the beam even at extreme depths.

Table 1. Attenuation Coefficients (at 1 MHz)

Material	dB cm ⁻¹
Bone	20
Air	12
Muscle	1.2
Brain	0.9
Fat	0.6
Blood	0.2
Water	0.002

deeper tissue penetration (e.g., subgluteal region) at the expense of fine axial resolution. Therefore, probe selection is always a trade-off between axial resolution and depth of penetration. When performing a peripheral nerve block, choose the probe and settings with the highest possible frequency that will still afford adequate depth penetration for imaging of the target nerve. See Figure 8 for an example of an ultrasound interface that allows the operator to control the frequency (wavelength) of the ultrasound. Most ultrasound systems allow the operator to change through multiple frequencies for a given probe.

Lateral resolution (Fig 10) refers to the machine's ability to distinguish 2 objects lying beside one another, perpendicular to the ultrasound beam.⁵ Lateral resolution is always worse than axial resolution, thus contributing to more clinical challenges. Despite the generated 2-dimensional image, modern ultrasound machines emit a 3-dimensional ultrasound beam that diverges as it propagates through the body (Fig 11). When electronically launched in various sequences and

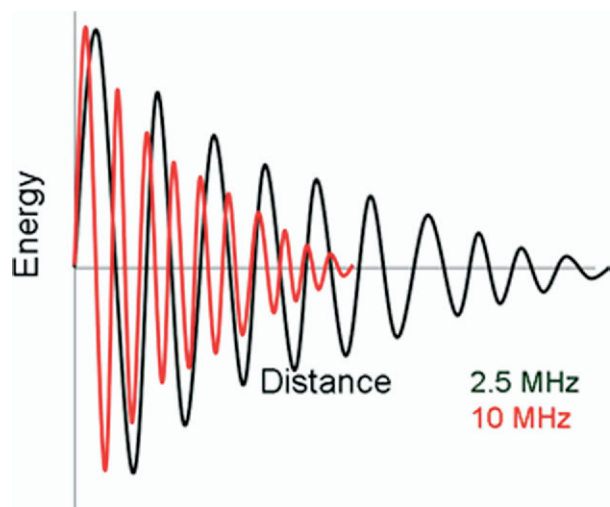


Fig 7. Attenuation. Attenuation is estimated as $\alpha \times f \times$ path length, where f is the frequency of the ultrasound wave and α is the attenuation coefficient. Notice the lower frequency wave (2.5 MHz) has less attenuation at a given distance when compared with the 10 MHz wave. Thus, the 2.5 MHz wave is able to penetrate the tissue more effectively than the 10 MHz wave.




Fig 8. An image of a typical ultrasound interface. (1) Probe frequency control. In the depicted system and probe, the frequency can be adjusted from 3 MHz to 12 MHz. The wavelength can not be adjusted independently; however, manual adjustments to frequency result in corresponding changes in wavelength. (2) Overall gain button. This dial changes how bright or dark the entire image appears. (3) Depth control. The objective is to set the depth to just below the target of interest, thereby optimizing temporal resolution. (4) Focus button. It is important to position the focus of the ultrasound beam at the same level as the target of interest. This will optimize both lateral and axial resolution. (5) Time gain compensation. These toggle dials control the gain at consecutive depth intervals. The top dials control the superficial gain and the bottom dials control deeper gain. Because attenuation occurs more with deeper imaging, the typical pattern of the time gain compensation dials is a progressive increase in gain as indicated in this figure.

patterns, the collective beams generated from the multiple piezoelectric elements in the transducer will produce the 3-dimensional beam. The shorter the distance between 2 adjacent element beams, the better the lateral resolution. High frequency and focused ultrasound beams generate the narrowest beams, thus maximizing lateral resolution.

Clinical pearls: The focal zone of the ultrasound beam, indicated on most screen displays, represents the narrowest part of the beam and should be positioned at the exact level of the target nerve. See Figure 8 for an example of the focus button on an ultrasound machine. The focus icon that is displayed on the ultrasound screen is shown in Figures 4 and 5 of Part II.²

The limitations of temporal resolution may impact the regional anesthesiologist. Temporal resolution is directly related to the frame rate of the ultrasound machine. The frame rate of a system characterizes how quickly an imaging device produces unique consecutive images called frames (in our case an image of needle, nerve, and local anesthesia). High frame rates are critical in cardiac

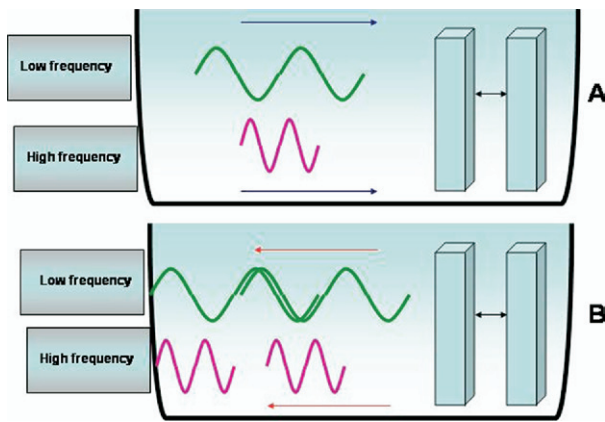


Fig 9. Axial resolution is the ability to discern objects in-line with the axis of the ultrasound beam. The axial resolution of an ultrasound wave is dependent upon wavelength (λ), frequency (f), and the speed of ultrasound in tissue (c). In human tissue $c = 1,540$ m/sec, and, therefore, $\lambda = c/f$. Axial resolution is roughly described as one half of the pulse length in mm. (A) A low frequency and a high frequency pulse (2-cycle pulse which is equal to 2λ) propagating toward 2 rectangular objects. (B) The waves returning toward the probe following the reflection off of the objects. The blue arrows depict the ultrasound pulse traveling toward the two objects and the red arrows depict the ultrasound traveling back toward the transducer. The lower frequency ultrasound has a wavelength that is larger than the distance between the objects (indicated by the black arrows). Therefore, the returning signal from both objects will overlap, and, therefore, the probe will interpret this signal as a single object. The higher frequency pulse discerns 2 separate objects because the wavelength is much shorter than the distance between the 2 objects and the returning waves will not overlap.

ultrasound because of the rapid motion of the heart. As the frame rate decreases, motion-related events become progressively blurred. During nerve blocks, motion occurs with probe movement, needle insertion, and injection of local anesthesia. Therefore, during these critical moments, a low frame rate could result in an ambiguous image. The temporal resolution (frame rate) is limited by the sweep speed of the ultrasound beam. In turn, the sweep speed of the ultrasound beam is limited by the speed of sound in tissue, as the ultrasound from the deepest aspects of the image must return to the probe before the next pulse is generated in the neighboring beam. The sweep speed can be increased by reducing the number of individual piezoelectric elements that make up the larger global beam sector or by decreasing the sector scanning angle (for phased array probes). The first option decreases the lateral resolution and the second decreases the image field width, underscoring the fundamental concept that temporal resolution

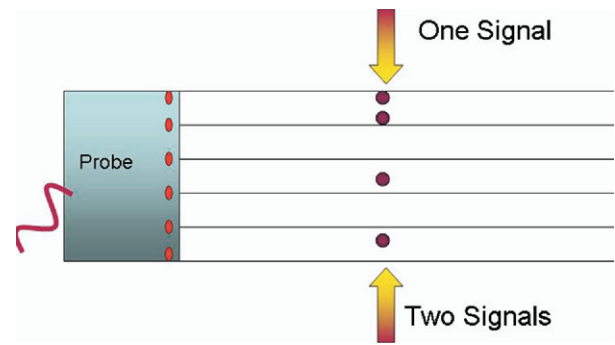


Fig 10. Lateral resolution is demonstrated here for a hypothetical linear ultrasound transducer. The ability for the ultrasound machine to correctly display 2 objects as separate structures depends on the relative distance between individual piezoelectric crystals versus the distance between the objects. The top 2 structures in this example will be imaged as one structure because each falls within surrounding crystal beams. The red ovals indicate the individual piezoelectric crystals. For illustration purposes, this figure represents a fictitious situation in which there is no focal zone or divergence of the ultrasound beam.

cannot be increased without a compromise secondary to principles of physics.

Clinical pearls: The main maneuver the anesthesiologist can perform to improve the temporal resolution is to decrease the imaging depth to just below the target(s) of interest (Fig 8). Additionally, the injection of local anesthetic should be slow, so as to minimize high velocity tissue movement which can blur the real-time image.

Color Doppler

Doppler technology allows for the identification and quantification of blood flow. In essence, the Doppler principle states that if an ultrasound pulse is sent out and strikes moving red blood cells, the ultrasound that is reflected back to the probe will

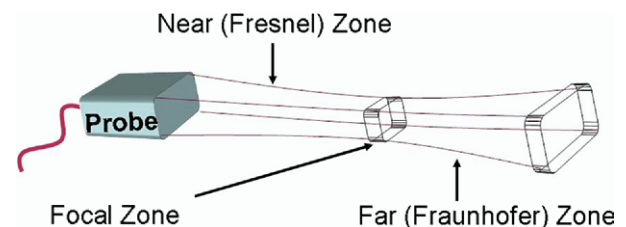


Fig 11. Characteristics of an ultrasound beam. The focal zone is where the ultrasound beam width is narrowest and demarcates the near zone (Fresnel zone) from the far zone (Fraunhofer zone). It is also the area of the best lateral resolution because the beam width is the narrowest at this location. Once the beam extends beyond the focal zone, lateral resolution begins to deteriorate due to divergence. This figure represents a prototypical electronically-focused ultrasound beam.

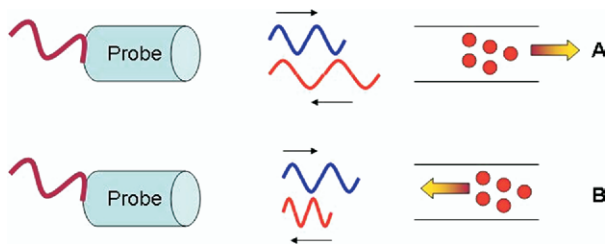


Fig 12. The Doppler effect. Doppler is used to measure velocity and directionality of objects. In the human body Doppler is most commonly used to measure velocity of blood flow. (A) The signal from fluid moving away from the probe will return at a lower frequency than the original emitted signal. (B) The signal contacting fluid moving towards the probe will return at a higher frequency than the original emitted signal. It is also important to note that the cosine of 0 degrees is 1 and the cosine of 90 degrees is 0. Therefore, as the angle approaches 90 degrees large errors are introduced into the Doppler equation (see Doppler formula).

have a frequency that is different from the original emitted frequency (Fig 12). This change in frequency is known as the Doppler shift.⁶ It is this frequency change that can be used in cardiac and vascular applications to calculate both blood flow velocity and blood flow direction.⁷ The Doppler equation states that:

$$(2) \text{ Frequency shift} = (2 \cdot V \cdot F_t)(\cosine\Phi)/c$$

Where V is the velocity of the moving object, F_t is the transmitted frequency, Φ is the angle of incidence of the ultrasound beam and the direction of blood flow, and c is speed of ultrasound in the media.

*Clinical pearls: The most important application of Doppler technology for the regional anesthesiologist is to confirm the absence of blood flow in anticipated trajectory of the needle, rather than the quantification of the actual velocity or direction of this flow. Doppler information is complicated by the frequent occurrence of artifact generation.*²

Summary

In summary, in order to optimize clinical imaging and to appreciate ultrasound-related pitfall errors

and artifacts, a solid understanding of the physics of ultrasound is extremely helpful. A 3-dimensional ultrasound beam is generated when many multiple tiny piezoelectric crystals rapidly vibrate in response to an electrical current. This ultrasound energy is transmitted through tissue where it is transmitted, reflected, scattered, refracted, and attenuated. Fortunately, some of the reflected ultrasound returns to the probe to be converted back to electrical energy. This electrical information is processed by the system's computer to ultimately generate the 2-dimensional image. The anesthesiologist has the ability to control image quality and appearance by interfacing with the system to change the characteristics of the ultrasound that is being sent out such as the frequency, focus, wavelength, and frame rate. In a similar fashion, the anesthesiologist has the ability to control how the returning image is processed by adjusting such variables as the gain and various proprietary post processing technologies.

References

1. Gray AT. Ultrasound-guided regional anesthesia. Current state of the art. *Anesthesiology* 2006;104:368-373.
2. Sites BD, Brull R, Chan VWS, Spence BC, Gallagher J, Beach ML, Sites VR, Abbas S, Hartman GS. Artifacts and pitfall errors associated with ultrasound-guided regional anesthesia. Part II: A pictorial approach to understanding and avoidance. *Reg Anesth Pain Med* 2007;32:419-433.
3. Weyman A. Physical principles of ultrasound. In: *Principles and Practice of Echocardiography*. 2nd ed. Philadelphia: Lippincott Williams & Wilkins; 1994:3-25.
4. Sutton M, Oldershaw P, Kotler M. *Textbook of Echocardiography and Doppler in Adults and Children*. 2nd ed. Cambridge: Blackwell Science; 1996:4-18.
5. Fiegenbaum H. *Echocardiography*. 5th ed. Philadelphia: Lea & Febiger; 1994:1.
6. Nanda N. *Doppler Echocardiography*. 2nd ed. Philadelphia: Lea & Febiger, 1993:7.
7. Perinno A, Reeves S, eds. *A Practical Approach to Transesophageal Echocardiography*. Philadelphia: Lippincott Williams & Wilkins; 2003:77-92.